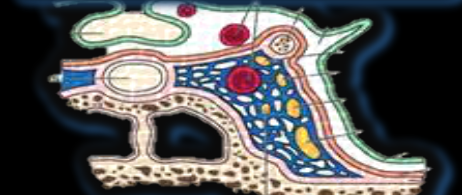
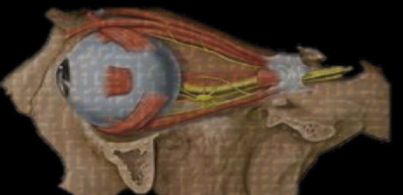
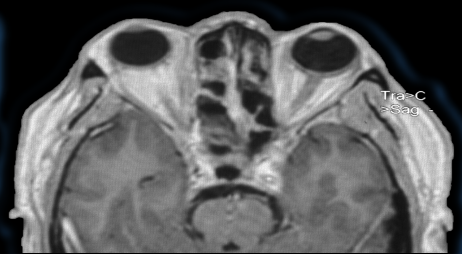


# Painful Oculomotor Cranial Neuropathies

Prof Vivek Lal  
Head, Dept. of Neurology  
Postgraduate Institute of Medical  
Education and Research (PGIMER)  
Chandigarh, India  
*vivekl44@yahoo.com*



Disclosures:

None

## Learning Objectives

- Is there a lesion ?
- Where is the lesion ?
- What's the lesion?

*Gordon Holmes (1905)*

# PAINFUL OPHTHALMOPLÉGIA

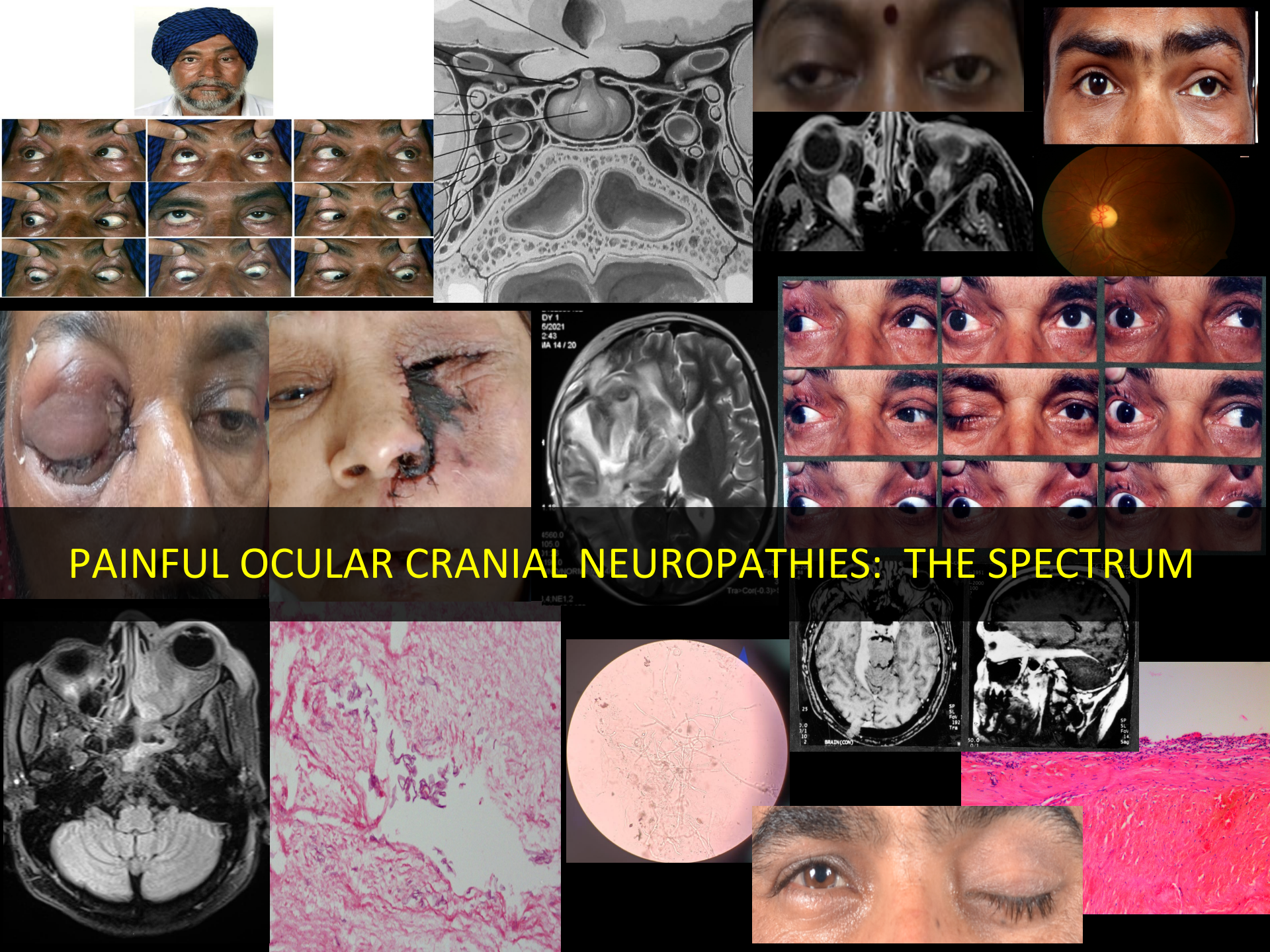
Key Substrates: Cranial Nerves, Extraocular Muscles, Pupils,

Defining - The Symptom

Decoding - The Signs

Targeted Investigations

Dedicated Management Protocols



# PAINFUL OCULAR CRANIAL NEUROPATHIES: THE SPECTRUM

# KEY MESSAGE

- A Diagnostic Dilemma: Protean manifestations
- Clinical Localization to Cause Recognition
- Dedicated Radiology
- Close Follow up In Clinically Relevant Scenarios  
(Specially Post Covid scenarios)

# REFERENCES

Jefferson G. On the saccular aneurysms of the internal carotid artery in the cavernous sinus. Br J Surg 1938;26:267-302.

Keane JR. Cavernous sinus syndrome. Analysis of 151 cases. Arch Neurol 1996;53:967-71.

Ishikawa H. Clinical anatomy of the cavernous sinus. Shinkei Ganka (Neuroophthalmol Jpn) 1996;13:357-63.

Bhatkar S, Goyal MK, .. Lal V. Which Classification of Cavernous Sinus Syndrome is Better - Ishikawa or Jefferson? A Prospective Study of 73 Patients. J Neurosci Rural Pract. 2016 Dec;7(Suppl 1):S68-S71. doi: 10.4103/0976-3147.196448.

Bhatkar S, Goyal MK, .. Lal V. Cavernous sinus syndrome: A prospective study of 73 cases at a tertiary care centre in Northern India. Clin Neurol Neurosurg. 2017 Apr;155:63-69. doi: 10.1016/j.clineuro.2017.02.017.

Bhatkar S, Mahesh KV, ... Lal V. Magnetic resonance imaging (MRI) versus computed tomographic scan (CT scan) of brain in evaluation of suspected cavernous sinus syndrome. Neuroradiol J. 2020 Dec;33(6):501-507. doi: 10.1177/1971400920970921.

Ranjan R, Singh D, Mahesh KV... Lal V. Infectious ophthalmoplegias. J Neurol Sci. 2021 May 21;427:117504. doi: 10.1016/j.jns.2021.117504.